

Exoerythrocytic Gametocytes of Saurian Malaria

SAM R. TELFORD, JR.

THE genus *Plasmodium* and the family Plasmodiidae are characterized by these features: "a sexual phase in the mosquito, and asexual cycles in tissue and blood cells of the vertebrate host; gametocytes are produced and are confined to mature erythrocytes. Malaria pigment is present in certain stages of the parasite" (Garnham, 1966, p. 65). Recent studies of saurian malarial species have provided exceptions to this classical definition. *Plasmodium mexicanum* of California lizards can complete sporogony and thus accomplish the sexual cycle in psychodid sandflies (Ayala and Lee, 1970). Two species of otherwise typical malarial parasites in Panamanian lizards apparently lack pigment in all stages (Telford, 1970). Findings reported here further indicate the necessity for taxonomic re-evaluation of the malarial parasites at both family and generic levels.

During study of approximately 500 malarial infections in Panamanian lizards, unpigmented gametocytes of at least three *Plasmodium* species were found occasionally in white blood cells of four host species, *Thecadactylus rapicaudus* (Gekkonidae), *Anolis biporcatus*, *A. poecilopus*, and *A. lionotus* (Iguanidae). Study of 58 malarial infections in Costa Rican lizards revealed exoerythrocytic gametocytes in *Anolis limifrons* and *A. aquaticus*.

An exoerythrocytic infection in an *Anolis biporcatus* was present at capture 1 April 1968 and persisted until death on 26 June 1969. Trophozoites, schizonts, and gametocytes of both sexes were seen in occasional thrombocytes throughout this period and increased significantly in abundance in the two months preceding the hosts death. An erythrocytic infection of *Plasmodium floridense* was present also at capture and until death, but often disappeared during the observation period.

All exoerythrocytic gametocytes observed in the Panamanian and Costa Rican anoles were in cells indistinguishable from thrombocytes (Figs. 3, 5-7). Those found in several geckoes, however, were confined to apparent lymphocytes (Fig. 9). Relationship of the exoerythrocytic parasites to the erythrocytic infections present in all hosts is not certain. *Anolis biporcatus* is commonly parasitized by *P. floridense* and *P. tropiduri*, often in mixed infec-

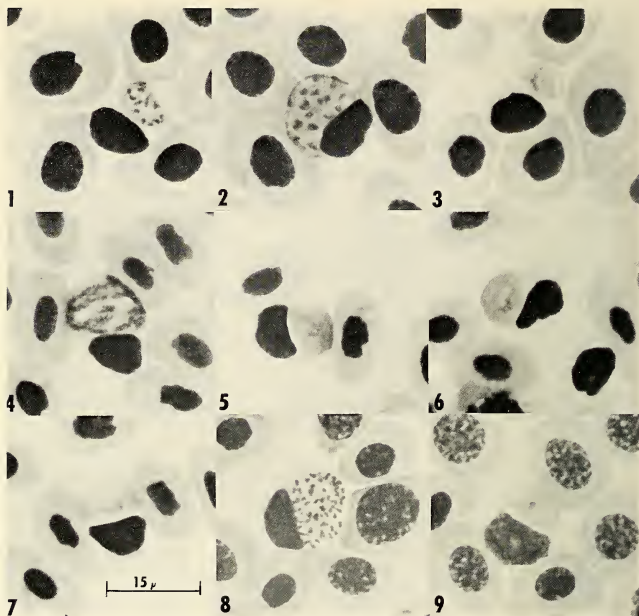


Fig. 1, 2, *Plasmodium* schizonts in thrombocytes of *Anolis lionotus*. Fig. 3, Macrogametocyte in thrombocyte of *A. lionotus*. Fig. 4, Schizont in thrombocyte of *Anolis biporcatus*. Fig. 5, 6, Macrogametocytes in thrombocytes of *A. biporcatus*. Fig. 7, Microgametocyte in thrombocyte of *A. biporcatus*. Fig. 8, Schizont in lymphocyte of *Thecadactylus rapicaudus*. Fig. 9, Macrogametocyte in lymphocyte of *T. rapicaudus*.

tions; *A. lionotus* and *A. poecilopus* share infection by *P. balli* and a smaller species which is probably *P. tropiduri*. A very different *Plasmodium* sp. parasitizes *T. rapicaudus*. The exoerythrocytic gametocytes of the anoles are almost identical in appearance among themselves (Figs. 3, 5-7) and are similar to those in the geckoes (Fig. 9), but the lymphocytic schizonts of *T. rapicaudus* (Fig. 8) contain many more nuclei than do those in anole thrombocytes (Figs. 1, 2, 4). The recently described haemosporidian genus *Saurocytozoon* from white cells of Brazilian lizards (Lainson and Shaw, 1969), in which only gametocytes were found, possibly represents a comparable phase of yet another saurian malaria.

Two interpretations are possible at present: (1) The exoerythrocytic forms represent one or (probably) more malaria-like species which parasitize white blood cells exclusively or (2) These stages are part of the mechanism whereby latent infections can again give rise to patent parasitemia of the erythrocytes. Further study of living infections is necessary for correct interpretation of the exoerythrocytic gametocytes, but it is already obvious that saurian malaras differ significantly in their biology from their relatives among the Aves and Mammalia.

ACKNOWLEDGMENTS

This study was supported in part by NIH grant AI-01251 to Gorgas Memorial Laboratory, and by Biomedical Science Support Grant (NIH) FR-07021-05 from the Division of Sponsored Research, University of Florida.

LITERATURE CITED

- AYALA, S. C., AND D. LEE. 1970. Saurian malaria: development of sporozoites in two species of phlebotomine sandflies. *Science*, vol. 167, pp. 891-892.
- GARNHAM, P. C. C. 1966. *Malaria parasites and other haemosporidia*. Blackwell Sci. Publ., Oxford, 1114 pp.
- LAINSON, R., AND J. J. SHAW. 1969. A new haemosporidian of lizards, *Saurocytozoon tupinambi* gen. nov., sp. nov., in *Tupinambus nigropunctatus* (Teiidae). *Parasitol.*, vol. 59, pp. 159-162.
- TELFORD, S. R. JR. 1970. Saurian malarial parasites in eastern Panama. *Jour. Protozool.*, vol. 17, no. 4, pp. 566-574.

The Florida State Museum and Department of Biological Sciences, University of Florida, Gainesville, 32601.

Quart. Jour. Florida Acad. Sci. 33(1) 1970